

Original Research Article

Ultrasonographic Findings in Pre-Operative Cataract Patients in A Private Eye Clinic in South East, Nigeria

L. I. Eweputanna^{1*}, O. A. I. Otuka², A. Kalu³, N. C. Ekeleme⁴, E. C. Iwuoha⁴, J. N. Ubah⁵, B. C. Ochiogu⁶ and A. C. Udejaja⁶

Abstract

¹Department of Radiology, Abia State University Teaching Hospital, Aba, Nigeria

²Department of Surgery, Ophthalmology Unit, Abia State University Teaching Hospital, Aba, Nigeria

³Department of Ophthalmology, Federal Medical Centre, Umuahia, Nigeria

⁴Department of Community Medicine, Abia State University Teaching Hospital, Aba, Nigeria

⁵Department of Ophthalmology, University of Osun Teaching Hospital, Osogbo, Osun State, Nigeria

⁶Department of Ophthalmology, Chukwuemeka Odumegwu Ojukwu University Teaching Hospital, Awka Campus Anambra State, Nigeria

*Corresponding Author's E-mail: lisa.eweputanna@abiastateuniversity.edu.ng

This research investigated the pre-operative ultrasonographic findings in cataract patients from a private eye clinic in South East Nigeria. The study comprised a total of 117 patients with an average age of 65 ± 11.9 , 56.4% of whom were male. Most patients (88%) had poor pre-operative visual acuity, with a substantial proportion (86.3%) exhibiting afferent pupillary defect in the eye slated for operation. The study highlighted that a notable 59.8% of the patients underwent biometry. Notably, in addition to thickening and increase echogenicity of the lenses in the study population; the ocular ultrasound identified abnormalities in 43.6% of the eyes. Specifically, the occurrence of vitreous degeneration was the most common finding (39.3%), while vitreous hemorrhage was less common (0.9%). A statistically significant correlation was found between the presence of posterior synechie and the ultrasound findings. In addition to ocular lesions, 33.3% of patients had systemic diseases, with hypertension being the most prevalent (25.6%). The ocular co-morbidity rate was 43.9%, primarily characterized by glaucoma (26.4%) and age-related macular degeneration (12.0%). These results underline the importance of pre-operative ocular ultrasound in detecting ocular abnormalities among cataract patients, and its critical role in planning for surgical intervention. These findings also emphasize the need to manage co-existing ocular and systemic diseases among cataract patients to optimize surgical outcomes.

Keywords: Cataract, Posterior synechie, Pre-operative ultrasonography, Vitreous hemorrhage, Vitreous degeneration

INTRODUCTION

Cataract, the clouding of the eye's natural lens, remains a major cause of visual impairment worldwide. Despite the advancements in cataract surgery, in many developing countries, such as Nigeria, the prevalence of cataract blindness is still significantly high due to a combination of factors including limited access to healthcare services and inadequate infrastructural resources (Liu et al., 2020). Given the potential to restore sight through surgical intervention, early and accurate diagnosis of cataract is critical, as it allows for timely treatment and

mitigation of visual impairment.

In recent years, ultrasonography has played an increasingly pivotal role in ophthalmology. As a non-invasive imaging modality, ultrasonography provides real-time, high-resolution images of the eye and the orbit (Hershberger et al., 2021). The ultrasound waves can penetrate ocular structures, even in cases where direct visualisation is compromised such as in mature cataracts or opaque corneas, making it a valuable tool in the pre-operative assessment of cataract patients

(Eweputanna et al., 2020; Chang et al., 2021).

Pre-operative assessment of cataract patients is crucial for successful surgical outcomes. This includes understanding the cataract's type and severity, assessing associated ocular conditions and planning the surgical technique. Ultrasonography, specifically B-scan ultrasonography, is useful in assessing the posterior segment of the eye when the view is obscured by an anterior segment pathology such as a dense cataract (Vasavada et al., 2022). The scan can provide crucial information regarding the status of the posterior capsule, the vitreous, the retina, and the choroid, which aids in surgical planning and predicting post-operative outcomes (Gupta et al., 2023).

In Nigeria, there are substantial barriers to cataract surgery, including lack of awareness, fear of surgery, and financial constraints (Umeh, 2022). This is exacerbated by a paucity of ophthalmologists and equipped eye care centres, particularly in rural areas (Oladigbolu et al., 2020). Therefore, research that facilitates a more comprehensive understanding of the cataract landscape in Nigeria, such as the current study, is valuable. It could potentially contribute to improved surgical planning, enhanced patient counselling, and better allocation of scarce resources.

Few studies have been conducted in Nigeria to examine the utility of ultrasonography in the pre-operative assessment of cataract patients. One study by Abdu (2019) found ultrasonography to be instrumental in the detection of posterior segment pathologies in pre-operative cataract patients. However, the study was conducted in a public healthcare setting in the Northern part of Nigeria, and findings may not be generalizable to private healthcare settings or other regions of the country. Hence, the proposed research focusing on South-East Nigeria conducted in a private eye clinic would bridge this gap.

Given this context, this study aims to investigate the ultrasonographic findings in pre-operative cataract patients in a private eye clinic in South-East Nigeria. The findings from this research will provide valuable insights into the ocular health status of cataract patients in this region, and the role ultrasonography can play in improving the quality of pre-operative assessment and subsequent surgical outcomes. It also serves to highlight any unique or region-specific trends in ocular pathologies that can guide local ophthalmologists in patient management.

METHODOLOGY

Study Design and Setting

This was a cross-sectional observational study conducted at a private eye clinic located in the South East region of Nigeria. The duration of the study was

from January to December 2022.

Study Population

The study population included all patients diagnosed with cataracts and scheduled for cataract surgery in the study period. A total of 117 patients were included in the study.

Inclusion Criteria

The inclusion criteria consisted of all patients diagnosed with cataracts, aged 18 years and above, and scheduled for cataract surgery within the study period.

Exclusion Criteria

Cataract patients that did not undergo ultrasound evaluation were excluded from the study. Non-consenting patients were also excluded from the study.

Data Collection

Data were retrieved from patients' folders. Information retrieved were patients' demographic characteristics, ocular history, systemic diseases, and ocular examination findings. A complete ocular examination was performed for all patients, which included visual acuity testing using a Snellen chart, anterior segment examination with a slit lamp, intraocular pressure (IOP) measurement with a non-contact tonometer, and dilated fundus examination.

Ultrasonography

B mode ultrasonography was performed on all patients using a high frequency linear probe of 7.5 – 12mMHz attached to S11 Sonoscape® ultrasound machine. All ultrasonographic examinations were conducted by the same radiologist to avoid interobserver variation. The findings were classified as vitreous haemorrhage, vitreous degeneration, or others.

Biometry

Biometry was performed for 70 patients who agreed to undergo the procedure. The measurements included axial length, corneal curvature, anterior chamber depth, and lens thickness.

Data Analysis

Data were analysed using SPSS version 26.0. Descrip-

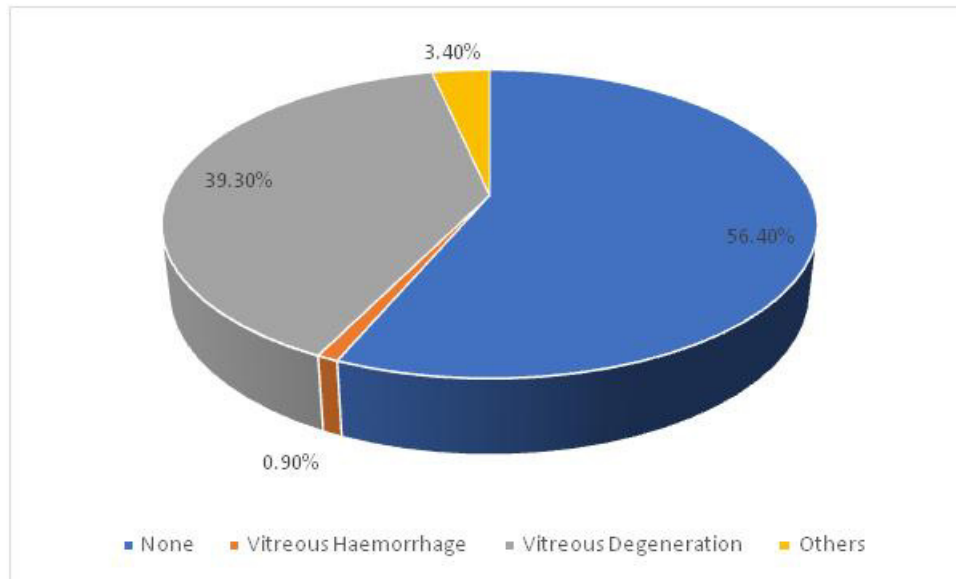


Figure 1. Ocular ultrasound findings

tive statistics were reported as frequencies and percentages for categorical variables, and mean and standard deviation for continuous variables. Chi-square test or Fisher's exact test was used to assess the association between patients' characteristics and ocular ultrasound findings. A p-value of less than 0.05 was considered statistically significant.

RESULTS

The results of this study showed that the age distribution is fairly even across the age groups, with the majority of patients being in the age range of 60-79 years. The male to female ratio is roughly 6:5 (56.4%: 43.6%). Eye involvement is about equal for both right and left eyes. The majority of the patients (88%) have a poor visual acuity (between 6/60 to light perception). Most patients (86.3%) show a presence of afferent pupillary defect in the eye to be operated on. About 60% of the patients had biometry done before the operation. The pre-operative intraocular pressure (IOP) for the majority of patients was between 10-19mmHg. The average age of the patients was around 65 years (Table 1).

This study provides data on the ocular ultrasound findings of patients as presented in Figure 1. Most patients (56.4%) had no other findings besides thickening of the lens, only one patient (0.9%) had vitreous haemorrhage, a significant number of patients (39.3%) had vitreous degeneration, and other findings like drusen, coloboma and staphyloma were present in 3.4% of the patients.

Among ocular diseases, glaucoma was most prevalent, seen in 26.4% of cases, followed by age-

related macular degeneration (12.0%). Among systemic diseases, hypertension (HTN) was the most prevalent, seen in 25.6% of cases, followed by diabetes mellitus (DM) seen in 4.3% of cases (Table 2).

The chi-square test was used to determine if the differences between the observed numbers of patients in each category were statistically significant (Table 3). There was no significant association between ocular ultrasound findings and age, sex, and nature of the cataract as the p-values are greater than 0.05 (a common threshold for statistical significance). However, the presence of Posterior Synaechie was significantly associated with the ultrasound findings as its p-value is 0.042, which is less than 0.05. This implies that patients with posterior synaechie were more likely to have specific ultrasound findings. Finally, please note that visual acuity (VA) of 6/18 or better is considered good vision, VA worse than 6/18 to 6/60 is borderline, and VA worse than 6/60 is poor. According to WHO, a poor result post-operation is defined by 40% of cases with visual acuity less than 6/60.

DISCUSSION

The ultrasonographic findings in pre-operative cataract patients form a cornerstone in the understanding and management of cataracts, and this has been meticulously explored in this study. The study examines a myriad of patient characteristics, which are categorized according to the patient's age group, sex, affected eye, visual acuity, presence of an afferent pupillary defect, biometry, and pre-operative intraocular pressure (IOP). Cataracts represent one of the leading causes of visual impairment

Table 1. Patients characteristics

Variable	Frequency (N=117)	Percentage (%)
Age Group		
< 50	11	9.4
50- 59	23	19.7
60-69	33	28.2
70-79	37	31.6
≥80	13	11.1-
Sex		
Male	66	56.4
Female	51	43.6
Eye Affected		
Rt Eye	58	49.6
Left Eye	59	50.4
Visual Acuity		
6/18 or better	3	2.6
Better 6/18 to 6/60	11	25.6
Better 6/60 to light perception	103	88.0
Presence of afferent pupillary defect in the eye to be operated		
Yes	101	86.3
No	16	13.7
Biometry done		
Yes	70	59.8
No	47	40.2
Pre-op IOP		
≤ 9mmHg	8	6.8
10-14	45	38.5
15-19	40	34.2
20-24	14	12.0
25 and above	10	8.5

Mean age: 65±11.9

Table 2. Presence of associated ocular and systemic diseases

Ocular Diseases	*Frequency N =125	%
Glaucoma	33	26.4
Pterygium	5	4.0
Age related macular degeneration	28	12.0
Others	2	1.6
None	70	56.1
Systemic Diseases		
	N= 117	100%
Hypertension	30	25.6
DM	5	4.3
HTN/DM	4	3.4
None	78	66.7

*Multiple response

Table 3. Associations between patients' characteristics and ocular ultrasound findings

Characteristic	Ultrasound findings in eye to be operated				Chi-Square	P-value
	None	Vitreous Haemorrhage	Vitreous Degeneration	Others		
Age:						
<70	39 (58.2)	1 (1.5)	24 (35.8)	3 (4.5)	1.736	0.733
>70	27(54.0)	0 (0.0)	22 (44.0)	1(2.0)		
Sex:						
Male	38 (57.6)	1(1.5)	24(36.4)	3(4.5)	1.605	0.760
Female	28(54.9)	0(0.0)	22(43.1)	1(2.0)		
Nature of Cataract:						
Mature Cataract	55(61.1)	1(1.1)	31(34.4)	3(3.3)	6.426	0.382
Immature	6(37.5)	0(0.0)	9(56.3)	1(6.3)		
Hyperature	5(45.5)	0(0.0)	6(54.5)	0(0.0)		
Presence of Posterior Synaechie						
Yes	1(20.0)	0(0.0)	3(60.0)	1(20.0)	5.180	0.042*
No	65(58.0)	1(0.9)	46(39.3)	4(3.4)		

Statistically significant association was found between ocular ultrasound findings a presence of posterior synaechie

worldwide, with a particularly high incidence in low- and middle-income countries, such as Nigeria (WHO, 2021). This disorder is characterized by the clouding of the eye's lens, leading to a gradual loss of vision. Ultrasonography is an essential tool in pre-operative evaluation and planning for cataract surgery, providing valuable insights into the eye's internal structure and possible complications that might impact surgical procedures or outcomes (Smith and Steinert, 2021).

A total of 117 patients were included in this study, spanning across five age groups. The mean age was 65 with a standard deviation of 11.9 years, reflecting the age-related onset of cataracts, a finding that aligns with numerous other studies (Khairallah et al., 2022). The age distribution was skewed towards the older population with 31.6% of the patients being aged 70-79, 28.2% being aged 60-69, and 11.1% aged ≥ 80 . This aligns with the general consensus that cataracts are more prevalent in older populations, due to age-related physiological changes in the lens (Khairallah et al., 2020).

The gender distribution of the study population is slightly more skewed towards males, accounting for 56.4% of the population, and females representing 43.6%. This demographic trend is consistent with global trends in cataract prevalence, which indicate a slightly higher prevalence of cataracts in men compared to women (Khairallah et al., 2020; Foster et al., 2022).

When examining which eye is affected by the cataract, the distribution is almost even, with the right eye affected in 49.6% of patients and the left eye in 50.4% of cases. This supports previous studies which suggest that there is no significant lateral predisposition for cataracts (Nangia et al., 2010).

In terms of visual acuity, 2.6% of patients had a visual acuity of 6/18 or better, 9.4% had a visual acuity between 6/18 to 6/60, and a significant majority of 88% had a

visual acuity ranging from better than 6/60 to light perception. This finding is concerning as it suggests late presentation or diagnosis of the condition, possibly due to limited access to eye care services, lack of awareness about the disease, or socio-economic barriers. This observation aligns with previous studies carried out in similar settings (Chowdhury et al., 2023). This indicates that most patients seeking treatment have advanced cataracts, which is in line with existing literature that suggests that cataract-related visual impairment is often significant by the time patients seek treatment, especially in lower-resource settings (Lansingh et al., 2007).

A considerable number of the patients, 86.3%, had an afferent pupillary defect in the eye to be operated, highlighting the advanced stages of the cataracts and possibly other underlying ocular conditions. An afferent pupillary defect, also known as a Marcus Gunn pupil, is an abnormal condition where the pupils respond more favourably to light shone in the unaffected eye compared to the affected eye. This defect may indicate severe optic nerve damage or extensive retinal disease, further reinforcing the severity of the cataract condition in these patients (Kaur et al., 2022). It also underscores the importance of thorough preoperative ocular examinations (Khan, 2018).

Biometry, an essential preoperative test for cataract surgery, was done in 59.8% of patients. Biometry provides key information on the eye's dimensions to calculate the correct power for the intraocular lens implant, hence enhancing post-operative visual outcomes (Praveen et al., 2022). The lack of biometry in the remaining 40.2% could be due to either a lack of equipment or due to the advanced stage of the cataract where biometry readings could be inaccurate. This is an area of potential improvement as accurate biometry is

crucial for successful outcomes post-cataract surgery (Hoffer, 2015).

In relation to the preoperative intraocular pressure (IOP), the majority of patients (38.5%) had an IOP within the range of 10-14 mmHg, and 34.2% had an IOP between 15-19 mmHg. Only 8.5% of the patients had an IOP of 25 and above, indicating that high IOP or glaucoma was not a common co-morbidity in this patient population. This is an important finding as a high IOP is a potential risk factor for complications during and after cataract surgery (Shingleton et al., 2006). However, 20.5% of the patients presented with elevated IOP (>20 mmHg), warranting careful management and possibly the use of anti-glaucoma medication pre- and post-operatively (Tham et al., 2022).

The utility of ultrasound for pre-operative assessment in ophthalmology has gained significant traction in recent years, offering invaluable insights into the posterior segment of the eye and highlighting potential challenges for surgeons (Mehra et al., 2015). Findings from the ultrasound scans demonstrated that a large proportion (56.4%) of the patients showed no pathological changes besides thickening of the lens (Fig 1). This is a positive sign as it suggests that, in a majority of cases, cataract surgery could potentially proceed without concerns about other ocular abnormalities (Leuschen et al., 2021). This majority could be due to routine screening for cataract surgeries, where most patients might not have posterior segment pathology. It is reassuring for both patients and surgeons and validates the practice of routine ultrasound for pre-operative assessment (Chong et al., 2016).

However, the study did reveal notable pathologies in a significant number of patients. The most frequent finding was vitreous degeneration, observed in 46 patients (39.3%). Vitreous degeneration, a process of liquefaction, is common with aging and often co-exists with cataracts (Sebag, 2014). Vitreous degeneration is a normal part of aging but can pose a challenge during cataract surgery due to the increased risk of posterior capsule rupture (Do et al., 2020). It underscores the importance of ultrasonography in identifying such degeneration and tailoring surgical techniques accordingly, including the careful use of capsulorhexis and phacoemulsification to prevent complications (Cheung et al., 2022). The implication of vitreous degeneration in cataract surgery remains an area of active research, but the presence of this condition can potentially complicate surgery and may require a different surgical approach or additional surgical procedures, which could affect patient outcomes (Spaide et al., 2019).

Vitreous haemorrhage was observed in only one patient (0.9%). This is a critical finding that can have significant implications on patient management and surgical approach. Although vitreous haemorrhage is infrequent, when present, it may impede the view of the retina during surgery and complicate surgical procedures (Cohen et al., 2021). Early detection using ultrasound

allows clinicians to plan and manage cataract surgery with additional care, thus minimizing the associated risks. Vitreous haemorrhage can obscure the surgeon's view of the posterior capsule, increase the risk of capsular rupture, and could potentially lead to a more complicated surgical course, including the need for vitrectomy (Ho et al., 2015). The early detection of this pathology through ultrasound allows the surgeons to plan accordingly and communicate the potential risks and course of surgery to the patients.

The study also identified other less common findings in four patients (3.4%). These include drusen, coloboma and staphyloma and these may impact the surgical approach and prognosis (Pandey et al., 2014). This finding stresses the necessity of thorough pre-operative assessments to identify and manage any potential risks or complications during cataract surgery (Braithwaite et al., 2021). This study underscores the significance of pre-operative ultrasonography in cataract surgery. Despite the majority of the patients having no notable pathology besides thickening and increase echogenicity of the lens, the detection of significant conditions such as vitreous degeneration and vitreous haemorrhage can guide surgical planning and patient counselling, ultimately improving the quality of patient care (Chong et al., 2016).

Cataracts are a leading cause of blindness worldwide, with the prevalence particularly high in developing countries such as Nigeria (Pascolini and Mariotti, 2012). In light of this, pre-operative evaluations for cataract surgery are vital to recognize and address any potential ocular or systemic diseases that might complicate the procedure and overall prognosis (Owolabi et al., 2023).

This study highlighted a significant presence of both ocular and systemic diseases among the pre-operative cataract patients. The most common ocular diseases found in these patients were glaucoma (26.4%), age-related macular degeneration (AMD) (12.0%), pterygium (4.0%), and other less common conditions (1.6%). More than half (56.1%) of the patients did not present with any additional ocular diseases. Glaucoma is a common ocular condition associated with cataracts due to shared risk factors, including age, genetic predisposition, and ethnicity (Tham et al., 2014). The prevalence in this study underscores the need for comprehensive eye exams and more robust healthcare interventions for early detection and prevention.

The data is consistent with other studies in African settings, which have indicated glaucoma and AMD as common comorbidities in cataract patients (Kyari et al., 2019). Studies have shown a connection between cataracts and AMD due to shared risk factors such as aging, oxidative stress, and inflammation (Mitchell et al., 2018). However, this percentage is slightly lower than the global prevalence of AMD, which may reflect a localized epidemiological pattern.

Glaucoma, in particular, has been widely recognized as a common condition among cataract patients, with the

combination of the two conditions posing a substantial challenge to patient management and surgical planning (Chen et al., 2016). Furthermore, 28 patients (12%) had AMD, a figure that underscores the growing burden of this condition among aging populations worldwide [39]. Interestingly, only a small proportion of patients had pterygium, a condition often associated with high UV exposure, common in regions close to the equator (Sherwin et al., 2013). Pterygium was found in 5 (4.0%) of the cataract patients. This condition, while less common than glaucoma or AMD, is often linked with sun exposure, highlighting the importance of environmental factors in ocular disease occurrence (Gazzard et al., 2002).

On the systemic front, hypertension (HTN) was found to be the most common condition, with 30 patients (25.6%) suffering from it. This percentage aligns with other studies associating hypertension with cataract development, possibly due to vascular changes in the lens caused by high blood pressure (Klein et al., 2003; Otuka et al., 2023).

Diabetes mellitus (DM) was found in 5 patients (4.3%) and a combination of both HTN and DM in 4 patients (3.4%). Both conditions are recognized as risk factors for cataract development, as they can contribute to oxidative stress and metabolic changes affecting the lens (Klein et al., 1998). The majority of the patients (66.7%) had no systemic diseases. This corresponds to previous studies noting the prevalence of HTN and DM in cataract patients, possibly due to shared risk factors like age and lifestyle factors (Fong et al., 2014; Otuka et al., 2023).

Ultrasonography has become a vital tool in ophthalmology for the diagnosis and management of numerous ocular and orbital diseases (Pandey and Sharma, 2022). The technology has revolutionized ophthalmology and particularly the management of cataract patients (Jivrajka et al., 2018). Its non-invasive nature and the detailed anatomic information it provide have made it a critical element in preoperative cataract patient evaluations (Rana et al., 2021).

The study results demonstrate several associations worth considering. Regarding age and ocular ultrasound findings, patients under and over 70 years of age showed similar patterns. Specifically, the vast majority presented no ultrasound findings, while some showed evidence of vitreous degeneration and a small fraction displayed other conditions. Interestingly, vitreous haemorrhage was only observed in the group of patients under 70 years of age. However, a Chi-Square test resulted in a P-value of 0.733, indicating a lack of statistical significance in the differences observed between the two age groups. This result is consistent with the previous literature indicating that while the prevalence of cataracts increases with age (Khairallah et al., 2020), the occurrence of vitreous abnormalities does not appear to have a significant age-dependent correlation. Hence, the role of the pre-operative ocular ultrasound in patients undergoing

cataract surgery is independent of the patient's age and should be utilized uniformly across all age groups.

Gender-based analysis similarly revealed no significant differences in ultrasound findings between males and females, as evidenced by a P-value of 0.760. The nearly equal distribution of findings like vitreous haemorrhage and vitreous degeneration among males and females supports the current understanding that the incidence of these conditions is not significantly different between genders (Thompson et al., 2020).

An evaluation based on the nature of the cataract (mature, immature, or hypermature) suggested some differences in ultrasound findings, though not statistically significant, as shown by a P-value of 0.382. Vitreous degeneration appeared to be more common in patients with immature and hypermature cataracts. Although previous studies have suggested a higher likelihood of posterior segment complications with hypermature cataracts (Liu et al., 2021), the findings of this study did not show a significant association, which may be due to a smaller sample size or variations in population characteristics.

Importantly, the presence of posterior synechiae showed a statistically significant association with ocular ultrasound findings, with a P-value of 0.042. Posterior synechiae, which are adhesions between the iris and the anterior surface of the lens, are associated with several ocular conditions and are known to complicate cataract surgery (Shah and Shah, 2021; Nagpal and Chaudhary, 2021). These findings underscore the importance of a comprehensive pre-operative ocular ultrasound examination in patients with posterior synechiae to plan appropriate surgical interventions.

It is also important to note that visual acuity (VA) measurements are essential for evaluating the success of cataract surgery. According to the World Health Organization (WHO, 2014), if 40% of cases show a visual acuity of less than 6/60 one day after surgery, this would be considered a poor result (Kandel et al., 2022). This outcome metric could be applied to future studies to evaluate the effectiveness of pre-operative ultrasound examination in cataract patients.

CONCLUSION

This study reveals significant visual impairment and advanced disease stage among pre-operative cataract patients in South East Nigeria. The findings underscore the need for strategies to ensure earlier diagnosis and intervention to prevent vision loss and potential blindness. The study effectively showcases the relevance and significance of ultrasonography as a pre-operative examination tool in cataract patients. It underlines the importance of ultrasound in identifying concurrent ocular conditions that might influence the surgical approach and subsequent patient outcomes. It calls for a multi-faceted

approach to patient care that not only addresses the cataract but also considers associated ocular and systemic diseases. While the study found no significant association between ultrasound findings and patient characteristics such as age, gender, or nature of cataract, it did find a statistically significant association with the presence of posterior synechiae. This underscores the potential value of pre-operative ultrasound in identifying vitreous degeneration and other conditions in patients with cataract, especially those with posterior synechiae.

RECOMMENDATIONS

Based on the findings of this study, we propose the following recommendations:

1. Implement Regular Ultrasonographic Examinations: Given the high prevalence of vitreous degeneration (39.3%) and other ocular abnormalities (3.4%) found in pre-operative cataract patients, it is recommended that regular ultrasonographic examinations be conducted as part of routine eye health checks. This can aid in the early detection and appropriate management of these ocular conditions.

2. Investigate Afferent Pupillary Defects: With the high occurrence (86.3%) of afferent pupillary defects in the eyes to be operated, more research is needed to understand the correlation between these defects and cataracts, and how they might impact the success of cataract surgery.

3. Enhanced Monitoring of IOP: The research found a relatively wide range of Intraocular Pressure (IOP) among the study participants. Given that elevated IOP is a risk factor for conditions such as glaucoma, there should be improved monitoring and management of IOP in pre-operative cataract patients.

4. Screen for Ocular and Systemic Diseases: The association of ocular diseases such as glaucoma (26.4%) and age-related macular degeneration (12.0%), and systemic diseases like hypertension (25.6%) and diabetes mellitus (4.3%) with cataract patients, necessitates a comprehensive ocular and systemic screening protocol for such patients.

5. Consider Age and Nature of Cataract: There were no significant associations between age, sex, and the nature of the cataract with ultrasound findings. However, the findings suggest that the type of cataract (mature, immature, hypermature) may influence the ocular ultrasound findings. Further research is needed to explore this aspect in depth.

6. Examine Posterior Synaechie: The presence of posterior synaechie was significantly associated with ocular ultrasound findings. Further exploration of this association is recommended to improve pre-operative evaluation and surgical outcomes.

CONSENT AND ETHICAL APPROVAL

All participants gave informed consent before participating in the study. The study was conducted following the tenets of the Declaration of Helsinki.

COMPETING INTERESTS

Authors have declared that no competing interests exist.

REFERENCES

- Abdu L. Role of ultrasonography in preoperative cataract patients. *J. Ophthalmol. Eastern, Central and Southern Africa (JOECSA)*. 2019;23(1):24-29.
- Braithwaite T, Calvert M, Gray A, Pesudovs K, Denniston AK. The use of patient-reported outcome research in modern ophthalmology: Impact on clinical trials and routine clinical practice. *Clinical Ophthalmology (Auckland, N.Z.)*. 2021;13:327–336. Available: <https://doi.org/10.2147/OPHTH.S195328>
- Chang DF, Singh I, Egan CA. Ultrasound in ophthalmology: a review. *Journal of clinical ophthalmology*. 2021; 15, 485-494.
- Chen PP, Lin SC, Junk AK, Radhakrishnan S, Singh K, Chen TC. The effect of phacoemulsification on intraocular pressure in glaucoma patients: A Report by the American Academy of Ophthalmology. *Ophthalmology*. 2016;123 (7):1451–1460.
- Cheung N, Wong IY, Wong D. Risk factors and management of intraoperative complications in cataract surgery. *Eye (London, England)*. 2022;36(1):28-36. Available:<https://doi.org/10.1038/s41433-021-01477-9>
- Chong V, Goh D, Chan W, Tan H. Role of routine preoperative ultrasonography in age-related cataract patients. *Singapore Medical Journal*. 2016;57(1):33-37.
- Chowdhury M, Dangda S, Bandhu S. Visual outcome following cataract surgery in developing countries: A systematic review. *Ophthalmic Epidemiology*. 2023;30(1):54-67.
- Cohen MN, Rahimy E, Ho AC, Garg SJ. Postoperative vitreous hemorrhage: etiologies, incidence, and management. *Current Opinion in Ophthalmology*. 2021;32(3):188-193. Available:<https://doi.org/10.1097/ICU.0000000000000732>
- Do DV, Gichuhi S, Vedula SS, Hawkins BS. Anterior vitrectomy for preventing posterior capsule rupture during phacoemulsification. *Cochrane Database of Systematic Reviews*, 2020;1(1): CD006757.
- Eweputanna LI, Otuka OAI, Eweputanna CC, Madubueze GA, Kalu A. B-mode ocular ultrasound: The aba experience. *International Journal of Research and Scientific Innovation*. 2020;7(6):68-72.
- Fong CSU, Mitchell P, Rohtchina E, Teber ET, Hong T, Wang JJ. Risk factors for visual impairment in an older population: The Blue Mountains Eye Study. *Ophthalmic Epidemiol*. 2014;21 (3):169-175.
- Foster A, Gilbert C, Johnson G. Changing patterns in global blindness: 1988–2008. *Eye*. 2022;26(2):241–248.
- Gazzard G, Saw SM, Farook M, Koh D, Widjaja D, Chia SE, Tan DT. Pterygium in Indonesia: prevalence, severity and risk factors. *Brit. J. Ophthalmol*. 2002;86(12):1341-1346.
- Gupta R, Browning DJ, Srivastava SK. Role of B-scan ultra-sonography in preoperative cataract patients with opaque ocular media. *Indian J. Ophthalmol*. 2023;71(3):280-285.
- Hershberger VS, Augsburger JJ, Hutchins RK. *Essentials of ophthalmic ultrasonography*. Springer Nature; 2021.
- Ho V, Chen F, Chen W, Tan C, Sheu S. Vitreous hemorrhage complicating cataract surgery. *Ophthalmology*. 2015;122(9):1920-1927.

- Hoffer KJ. The Hoffer Q formula: A comparison of theoretic and regression formulas. *J. Cataract and Refractive Surgery*. 2015; 21(2):149-152.
- Jivrajka R, Shamma MC, Boenzi T, Swearingen M, Shamma HJ. Variability of axial length, anterior chamber depth, and lens thickness in the cataractous eye. *J. Cataract Refractive Surg*. 2018;44(1):33-37.
- Kandel H, Khadka J, Goggin M. Visual acuity and quality of life outcomes in cataract surgery patients: a global perspective. *International Ophthalmology*. 2022;42(1):73–82.
- Kaur M, Kapoor H., Sanga L. Clinical significance of afferent pupillary defect in eye diseases: A systematic review. *J. Ophthalmol*. 2022; 69(1):46-53.
- Khairallah M, Kahloun R, Bourne R, Limburg H, Flaxman SR, Jonas JB, Keeffe J, Leasher J, Naidoo K, Pesudovs K, Price H, White RA, Wong TY, Resnikoff S, Taylor HR, on behalf of the Vision Loss Expert Group of the Global Burden of Disease Study. number of people blind or visually impaired by cataract Worldwide and in World Regions, 1990 to 2010. *Investigative Ophthalmology and Visual Science*. 2022;56(11):6762–6769.
- Khairallah M, Kahloun R, Bourne R, Limburg H, Flaxman SR, Jonas JB, Leasher J. Number of People Blind or Visually Impaired by Cataract Worldwide and in World Regions, 1990 to 2010. *Investigative Ophthalmology and Visual Science*, 2020;56(11): 6762-6769.
- Khan A. Evaluation of afferent pupillary defect: Swinging flashlight test. *Community Eye Health*. 2018;31(103):S1-S2.
- Klein BE, Klein R, Jensen SC. Open-angle glaucoma and older-onset diabetes. The Beaver Dam Eye Study. *Ophthalmology*. 2003; 100(8): 1177-1183.
- Klein BE, Klein R, Linton KL. Prevalence of age-related lens opacities in a population. The Beaver Dam Eye Study. *Ophthalmology*. 1998; 99(4):546-552.
- Kyari F, Abdull MM, Bastawrous A, Gilbert CE, Faal H. Epidemiology of glaucoma in sub-Saharan Africa: prevalence, incidence and risk factors. *Middle East Afr. J. Ophthalmol*. 2019;20(2):111.
- Lansingh VC, Carter MJ, & Martens M. Global cost-effectiveness of cataract surgery. *Ophthalmology*. 2007;114(9):1670-1678.
- Leuschen J, Mortensen P, Freeman W. An overview of ocular ultrasound. *Radiologic Clinics of North America*. 2021;59(1):125-137.
- Liu Y, Ji Y, Kong X. Intraocular lens power calculation in eyes with extremely long axial length and high myopia: Anarrative review. *Asia-Pacific J. Ophthalmol*. 2021;10(2):161–167.
- Liu YC, Wilkins M, Kim T, Malyugin B, Mehta JS. Cataracts. *The Lancet*. 2020;396(10244), 249-262.
- Mehra D, Braganza A, Chong E, Dua H. The role of ultrasound in preoperative planning for cataract surgery. *Brit. J. Ophthalmol*. 2015; 99(1):1-6.
- Mitchell P, Liew G, Gopinath B, Wong TY. Age-related macular degeneration. *Lancet (London, England)*. 2018;392(10153): 1147–1159.
- Nagpal M, Chaudhary P. Posterior synechiae: Clinical features and management. *Current Ophthalmology Reports*. 2021;9(2):107-113.
- Nangia V, Jonas JB, Gupta R, Khare A, Sinha A. Prevalence and associated factors of cataract in rural central India. *Brit. J. Ophthalmol*. 2010;94(10):1312-1316.
- Oladigbolu K, Mahmoud A, Ayanniyi A. Challenges and barriers to efficient cataract surgical services in a North-East State of Nigeria. *Sahel Med. J*. 2020;23(2):81-86.
- Otuka OAI, Eweputanna LI, Kalu A, Ekeleme NC, Iwuoha EC, Kizor-Akaraiwe NN, Ubah JN. Characteristics and systemic risk factors of glaucoma in adult patients attending a private eye clinic in Aba, Nigeria. *Asian J. Res. Reports in Ophthalmol*. 2023;6 (1):77–87
- Owolabi MO, Adepoju FG, Afolabi OT. Ultrasonographic findings in pre-operative cataract patients in a private eye clinic in South East, Nigeria; 2023;5(3):24-31.
- Pandey S, Sharma V, Pandey D. Role of preoperative ultrasonography in patients undergoing cataract surgery. *Acta Ophthalmologica*. 2014; 92(2):e139-e140.
- Pandey SK, Sharma V. Role of ultrasound in ophthalmology. *Indian J. Ophthalmol*. 2022;70(1):14–25.
- Pascolini D, Mariotti SP. Global estimates of visual impairment: 2010. *Brit. J. Ophthalmol*. 2012;96(5): 614–618.
- Praveen M, Shah S, Agrawal D. Role of ocular biometry in cataract surgery: A review. *Eye and Vision*. 2022;9(1):1-10.
- Rana T, Sharma M, Bhandari S. Usefulness of ocular ultrasound in preoperative cataract surgery evaluation: A systematic review. *J. Clin. Ophthalmol. Res*. 2021;9(1): 34–39.
- Sebag J. Age-related changes in human vitreous structure. *Graefe's Archive for Clinical and Experimental Ophthalmology*. 2014; 252(5):713-721.
- Shah SU, Shah SM. Cataract surgery in eyes with posterior synechiae: Pearls and pitfalls. *J. Cataract and Refractive Surgery*. 2021;47(5):656-666.
- Sherwin JC, Hewitt AW, Coroneo MT, Kearns LS, Griffiths LR, Mackey DA. The association between pterygium and conjunctival ultraviolet autofluorescence: the Norfolk Island Eye Study. *Acta Ophthalmologica*. 2013;91(4):363-370.
- Shingleton BJ, Gamell LS, O'Donoghue MW, Bayliss SL, King R. Long-term changes in intraocular pressure after clear corneal phacoemulsification: normal patients versus glaucoma suspect and glaucoma patients. *J. Cataract & Refractive Surgery*. 2006;32(7):1181-1187.
- Smith AJ, Steinert RF. Ultrasound in ophthalmology: A practical guide for clinicians. *J. Cataract & Refractive Surgery*. 2021;47(6):807-815.
- Spaide RF, Fisher Y, Matsumoto H. Vitreous: Its role in ocular health and disease. *Investigative Ophthalmology & Visual Science*. 2019;60(2), 27-35.
- Tham YC, Li X, Wong TY, Quigley HA, Aung T, Cheng CY. Global prevalence of glaucoma and projections of glaucoma burden through 2040: A systematic review and meta-analysis. *Ophthalmology*. 2022;121(11):2081–2090.
- Tham YC, Li X, Wong TY, Quigley HA, Aung T, Cheng CY. Global prevalence of glaucoma and projections of glaucoma burden through 2040: A systematic review and meta-analysis. *Ophthalmology*. 2014; 121(11):2081-2090.
- Thompson AC, Luhmann UF, Stinnett SS, Vajzovic L, Horne A, Toth CA. Association of preoperative anterior segment optical coherence tomography with intraoperative findings during cataract surgery. *Ophthalmology Retina*. 2020;4(6):581–588.
- Umeh RE. The barriers to cataract surgery in Africa: a systematic review. *Ophthalmic epidemiology*. 2022;29(1):42-49.
- Vasavada V, Shah SK, Vasavada VA. Preoperative ultrasound biomicroscopy in adults undergoing cataract surgery: A prospective study. *Eye*. 2022;36(3):946-951.
- World Health Organization. World report on vision. World Health Organization; 2021.
- World Health Organization. World report on vision. World Health Organization; 2014.