

Original Research Article

Trans- nasal Versus Mini Plate and Screws Post Traumatic Medial Canthopexy, a Comparative Study

¹Mahdi Hameed Abood and ^{*2}Dana Abdulmagid Abdilkarim

Abstract

¹Al-Wasity Hospital for Reconstructive Surgery, Baghdad / Iraq, Consultant plastic surgeon

²Emergency Hospital for Burn and Plastic Surgery, Sulamanyah, Iraq, Plastic Surgeon

*Corresponding Author's E-mail:
dana_dr77@yahoo.com

Post traumatic Medial Canthal Tendon, MCT, rupture with telecanthus lead to aesthetic and functional impairment. The aim of the surgery is to restore anatomical structure of the medial canthal area to its natural and aesthetic form with preservation of function, for reinsertion or repositioning the medial canthal tendon that has been avulsed or displaced Tessier et al (1966) suggested trans-nasal canthopexy technique. It is a comparative clinical study to evaluate the trans-nasal medial canthopexy and mini plate and screws medial canthopexy that we suggest to reinsert the detached medial canthal tendon to its original bony attachment. Twenty war injured patients with unilateral telecanthus due to injured MCT attended to Al-Wasity hospital for reconstructive surgery and Emergency Hospital for Burn and Plastic Surgery Sulamanyah, Iraq, in the period from April 2003 and March 2012, divided to two groups, (10) cases for each group, reconstruction of the lesion using two different surgical techniques, trans-nasal canthopexy for group one and mini plate and screws canthopexy for group two. Patients were followed up for up to 2 years postoperatively. Functional and aesthetic improvement had been achieved with minimal complication noticed with mini plate and screws canthopexy; the surgical time, in average, was 45 minutes in group two, wire stripping was recorded with two patients in group one. Mini plate and screws canthopexy is a short surgical procedure provides precise alignment of the medial canthal tendon and provides better post-operative symmetrical appearance and better aesthetic and functional result can be gained.

Keywords: Medial Canthal Tendon/MCT, Mini Plate and Screws Canthopexy

INTRODUCTION

The medial part of the orbital region is a complex structure of several facial bones attachment for support of the eye and lacrimal collecting system (Robert, 1984).

The medial canthal ligament shares with capsule-palpebral fascia in the lower eye lid and levatoraponeurosis in the upper lid in supporting the tarsal plates and eyelids (Charles, 2002). Jones suggests that this structure should be recognized as a tendon rather than a ligament because it is considered as a connector for muscle (Robert, 1984). The Medial Canthal Tendon (MCT) provides globe support as a part of

suspensory sling, which is in continuity with the lateral canthal ligament, and upper and lower tarsal plates. The MCT and the orbicularis-oculi musculature perform as alacrimal pump. The MC is also important in maintaining the configurations of the palpebral opening, and it helps in the attachments of the orbicularis-oculi musculature. Post traumatic deformities are either the result or usually associated with disruption of the anatomical continuity of the medial canthal tendon (Gruss, 1982). Lateral displacement of the MCT and the unopposed contraction of the orbicularis muscle pull structures laterally (Joseph

et al., 1990), disruption of the skeletal anatomy of the medial canthal area, the underlying scar tissue resulting in linear contraction band (Glen and Byron, 1990). Malformation of lacrimal apparatus with epiphora, relaxation of the medial canthal soft tissue structures, and inability of the orbicularis muscle tone causes relaxation of the lower eyelid, eversion of lacrimal punctum, and inadequate evacuation of tears from the lacrimal lake that interference with the function of the orbicularis muscle also hampers the evacuation of the tears from the lacrimal sac into the naso-lacrimal duct (Joseph et al., 1990). The aim of surgery is to restore the anatomical structure of the medial canthal area to its natural and aesthetic form with preservation of function (Williamson et al., 1981). Tessier et al. (1962) suggested trans-nasal canthopexy surgical procedure to reinsert or reposition the MCT that has been avulsed or displaced (Robert, 1984). There is some difficulty in performing such a surgical procedure to reconstruct medial canthal ligament especially those with segmental loss of the tendon as all the patients were a war injury victims due to direct and indirect effect of blast injuries, we suggested mini plate and screw to reinsert or reposition the avulsed or the remaining part of damaged MCT. In this paper represent a comparative study between Tessier trans-nasal medial canthopexy surgical procedure and mini plate and screws medial canthopexy.

PATIENTS AND METHODS

Patients

Twenty patients with widening of the intercanthal distance were selected, and underwent surgical repair of medial canthal tendon by one of two surgical procedures, over a period of 24 months (from August 2003 to March 2012), half of them underwent trans-nasal canthopexy to reconstruct avulsed MCT and the other half treated by mini-plate and screws canthopexy. Inspection done to detect the visible deformity, deep palpation of upper mid face to identify the bone landmarks and to detect the bony abnormalities, bowstring test, comparison with the other side. These findings were confirmed by surgical exposure, and decision was made to choose the appropriate surgical procedure. Photographic recording was done that accurately documents the clinical situation pre-operatively, operatively and post-operatively for each patient.

Methods

Pre-operative measures

A detailed history was taken including the causative agent, emergency, complaint, duration, previous

operations, associated illness and complications. Physical examination which includes general evaluation of the patient for surgical fitness and local evaluation for aesthetic and functional abnormalities, including, the shape and the movement of the eyelids, visual impairment and movement of the eye were studied by ophthalmologic consultation. Measurements of canthal parameters which include outer canthal distance (OCD), inner canthal distance (ICD), Palpebral Fissure Length (PFL), naso-canthal distance (NCD), and Canthal Index (CI) which is calculated by $ICD/OCD \times 100$. The investigations related, included Hb level, pcv, blood group and Rh, bleeding time, clotting time, prothrombin time and Partial Thromboplastin Time (PTT), were done. One pint of cross-matched of whole blood prepared. Radiological imaging, included plain skull X ray, CT scan and MRI, were done if available, 500 mg ampiclox IV was given pre-operatively.

Surgical procedures

Under general anesthesia, pharyngeal pack, supine position and the head up 30-45 degree, marking, injection of adrenaline in 1:200,000 dilutions, to achieve a wide exposure of the lesion through the original facial scars, z-plasty incision or Mustardae approach.

Trans-nasal canthopexy: figure (1), after localization of MCT, it is transfixated by two stainless steel wires and then nasal trans-fixation may be achieved by a special awl using hand pressure or with a burr driven by an electrical motor. The level of the hole is easily determined with some trace of the lacrimal crest remainings or in case of a unilateral lesions, it is possible to obtain a point of reference from the MCT on the uninjured site. Since the level of perforation of the septum determines the direction of traction, it is essential to overcorrect both above and behind the desired level of trans-fixation.

On the opposite lateral nasal wall, the hole made at the level of the anterior lacrimal crest and in front of the tendon insertion. During the course of this maneuver the globes of the eyes must be carefully protected. The contra-lateral fixation: - by virtue of traction effected by the wires transfixing the tendon and passing across the nasal skeleton, the MCT is brought into close a positioning with the bone and at its correct level, the tow ends of the ligature wires are twisted together over a small toggle, a small plate or cinch pin which lies across the hole on the contra lateral side. The holding strength of the trans-nasal wire was assessed to be 74% of that of contra lateral intact MCT, i.e. this type of fixation provides excellent ultimate biomechanical strength.

Mini plate and screw canthopexy: After identification of avulsed or cut MCT, figure (2), or even fibrous tissue in

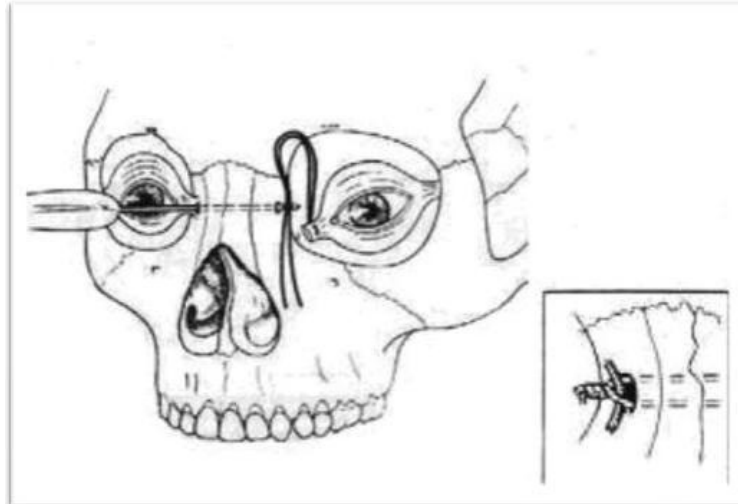


Figure 1. Trans-nasal fixation

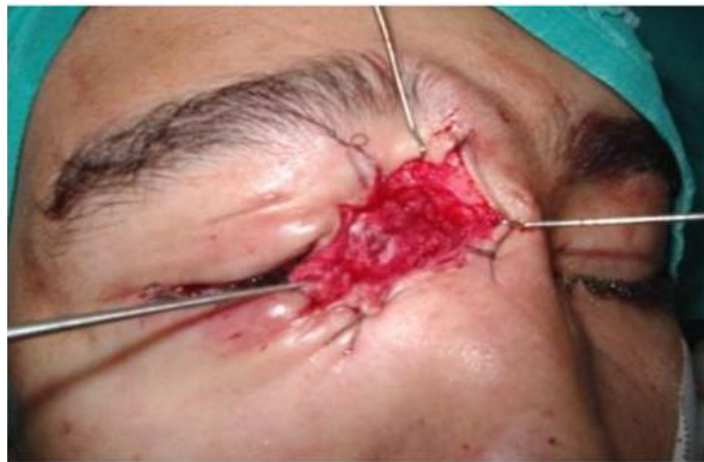

Figure 2. The destroyed MCT which is replaced by fibrous tissue.

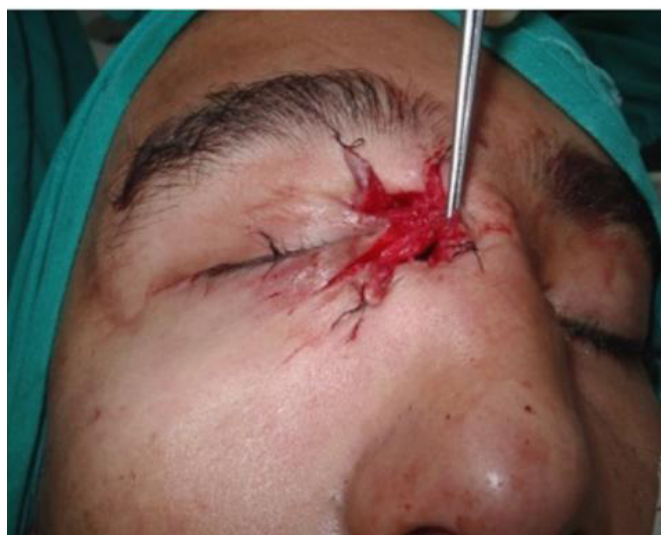

Figure 3. Fibrous tissue in continuity with MCT

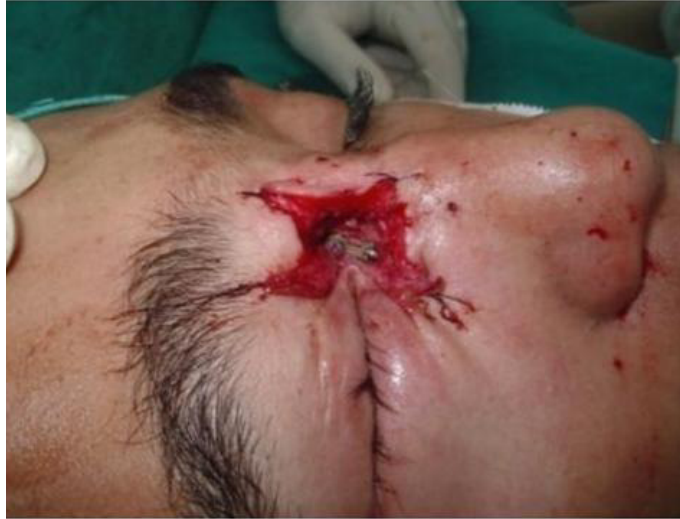

Figure 4. Fibrous tissue attached to MCT inserted beneath the plate from the posterior border.

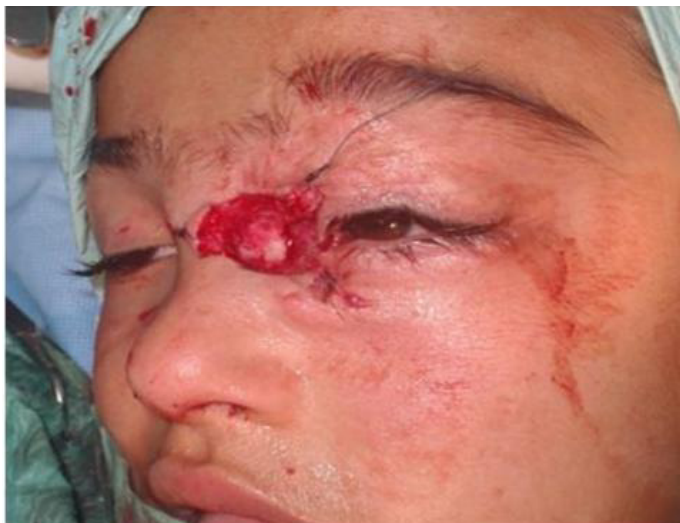

Figure 5. Showing exposure of bony part of medial canthal region.

continuity with damaged tendon figure (3).

Angular vessels ligated or cauterized by bipolar diathermy, Careful and detailed exposure of the bony part of the canthal region figure (5).

The bones are completely separated from its periostium. The field should be wide enough to fix the mini plate and screw, miniplate is chosen, it must have at least two holes, the site of the upper hole is identified, a hole is drilled across the bone, the plate is fixed by screw through the upper hole, the screw should not completely tightened figure (6),

The lower hole is drilled across the bone (the drill should be introduced in the central part of the hole). The medial canthal tendon, or the fibrous tissue attached to it, is inserted beneath the mini plate from the posterior

border, figures (4 and 7). The second screw inserted to the anterior plate hole and tightened figure (7). The length and the site of the tendon can be adjusted, symmetry is checked, and then the screws tightened completely, final check for symmetry is performed. During the course of this maneuver the globes of the eyes must be carefully protected, skin closed in layers figure (8), finally dressing is done.

Post-operative measures

Dressing is usually done with steri-stripe for the skin, gentamycin eye ointment, and occlusive eye dressing was put for few days. The patient was put in semi-sitting

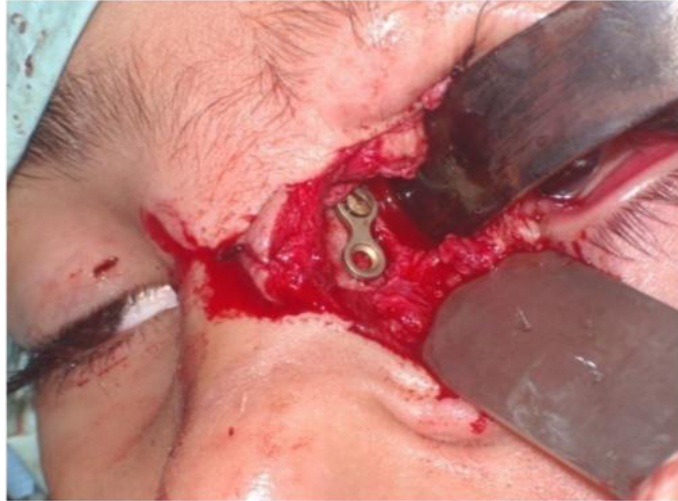

Figure 6. The plate is fixed by screw through the upper hole, the screw should not be completely tightened.

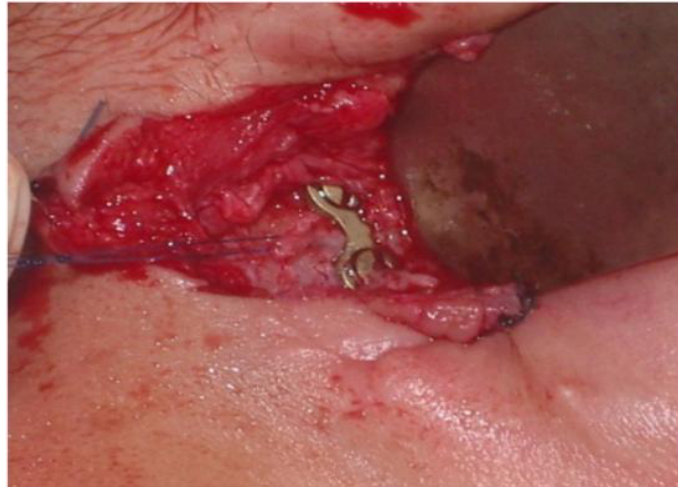


Figure 7. The medial canthal tendon inserted beneath the plate, the second screw inserted to the anterior plate hole and tightened.

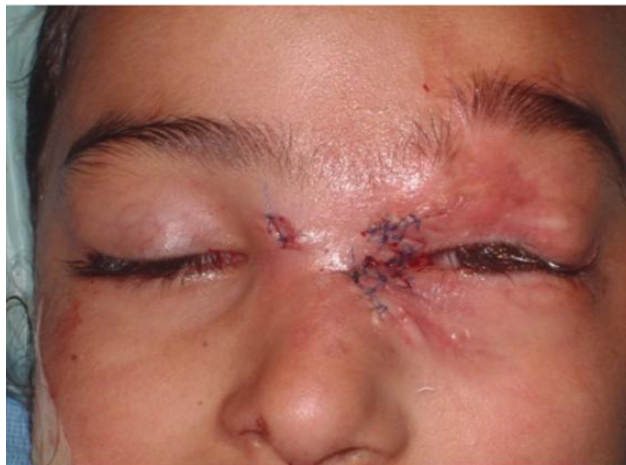

Figure 8. Final check for symmetry comparing with other side, Skin closed in layers.

Table 1. Sex distribution

Sex	No. of cases	% of total
male	12	60%
female	08	40%

Table 2. Distribution of cases according to the sides of the tendon

Repaired side	No. of cases	% of total
left	12	60%
right	08	40%

Table 3. Functional assessment

Group	No. of cases with pre-operative epiphora	% of pre-operative epiphora	No. of cases with post-operative epiphora	% of post-operative epiphora
Group one	06	60%	02	20%
Group two	07	70%	01	10%
Total	13	65%	03	15%

Table 4. Symmetry assessment

Group	No. cases with pre-operative asymmetry	% of cases with pre-operative asymmetry	No. of cases with post-operative asymmetry	% of post-operative asymmetry
Group one	10	100%	03	30%
Group two	10	100%	01	10%
total	20	100%	04	20%

position, and continues on antibiotic for 3 days in divided doses. All of the patients were fit to be discharged on 2nd post-operative day. The skin stitches were removed after 6-7 days in out-patient clinic. The patient were continued on antibiotic eye ointment and drops for two weeks, and they were followed up for 6-24 months post operatively, twice weekly in the first two months, once per week for the next month, and once monthly to once in three months for the next months, for evaluation of functional, aesthetic and numerical (biometric) assessment.

Assessment methods

The assessment was carried out by the same member of the team for functional, aesthetic and numerical, while the symmetry assessed by a known team member.

1. Functional assessment: post-operative absence of the epiphora that was present pre-operatively, this was chosen as a representative of functional recovery.
 2. Aesthetic assessment: depend on
 - a. Correction of rounded downward tilted medial canthus.
 - b. Abolition of epicanthal fold.
- 1- Symmetry, we depend upon a third eye for independent evaluation of Symmetry.

2- Numerical assessment: CI when it was 38 and above means severs telecanthus.

RESULTS

The total number of patients included in this study was (20). All were suffering from unilateral telecanthus due to MCT lesion. War injuries were the cause. Ten cases reconstructed by trans-nasal canthopexy, which represent group one, and the other 10cases reconstructed by mini plate and screws canthopexy, represent group two. Average operative time for trans-nasal canthopexy were 95 minutes while the average operative time for mini plate and screws canthopexy were 45 minutes. The epidemiological data is as follows (Table 1-6)

Post - operative complications other than those mentioned above were in group one which represents wire stripping in two cases and the operation repeated to both of them using button instead of toggle to provide adequate stabilization. Intense skin irritation, with unrelieved pain sensation, noticed in all cases where button were used. Associated injuries had been noticed in most of the cases, as all of them were the victim of blast injuries e.g. loss of eye in one case, sever damage

Table 5. Aesthetic assessment

Group	Pre-operative Epicanthal fold	Post-operative Epicanthal fold	Pre-operative Rounded angle	Post-operative rounded angle	Pre-operative deviated angle	Post-operative deviated angle
Group one	80%	20%	60%	20%	70%	20%
Group two	80%	10%	70%	zero	70%	zero
Total	80%	15%	65%	10%	70%	10%

Table 6. Canthal index measurement

Group	mean Pre-operative CI	mean Post-operative CI
Group one	40.20	33.72
Group two	40.10	31.05

to oculomotor nerve with ptosis of upper eye lid in two cases, nasoethmoidal fracture two cases, eye brow defect in three cases.

DISCUSSION

Surgical treatment of telecanthus poses one of the most demanding tasks in facial reconstruction due to anatomical complexity of the naso-orbito-ethmoid region (NOE) region, its paramount role in facial expression. This lead to aesthetic and/or even functional impairment and the relatively small amount of tissue in this region which makes it very difficult to carry out repeated number of the operations without incurring the risk of the destroying the benefits of the preceding intervention (Kala et al., 2000; Cohen et al., 1995). This is a clinical study, the results of which may not be statistically significant, as the number of cases studied is small and cannot reflect the actual percentage among population as we have many victims who cannot find their way to get proper surgical treatment.

Male to female ratio was 1.5:1 while the ratio was 4:1 as reported by Michael Bryan's study (Michael, 1996), and we think it does not reflect the actual ratio among the victims because the ladies and their families usually are more concerned about treatment for aesthetic and functional problem. High mid-face trauma are most often seen in young adult males, children have a low incidence due to the relative larger cranial size, high ratio between cranial and mid-face size and the lack of the complete maxillary sinus pneumatization (Michael, 1996). Regarding the age of the patients, 30% of the patients were below 10 years and 50% between 11-30 years old and 20% of patients were among those between (31-50) years, which reflect the conflict in our country as all the people are a target to the violence, while in Michael Bryan's study there was predominantly affliction of young's (20-40).

MRI is very beneficial especially in defining the image of the soft tissue states so it is the procedure of choice in

evaluating the lesion (Michael, 1996). In this series MRI done for 55% of the cases, because the instrument is not always available and working as we have maintenance problem. Regarding the surgical approach, the original scar was used in (5) cases which represent 25% of the cases and we chose this approach in hypertrophy and unsightly scar for aesthetic reason. Mustardae approach with two z-plasty in opposing direction constitutes a technique for releasing tension and contracture of linear scar. This is of particular usefulness in area where only small flaps may be designed, a limited amount of tissue in the confined naso-orbital valley limits the size of the two flap (Frodel, 1995). These approaches were used in 75% of the cases. Whatever the type of incision is used, it will be necessary to be followed by careful and detailed exposure of all bony lesion, elimination of any overlap of margins, and precise excision of all scar tissue (Evans, 1994). We think that Mustardae approach provide adequate exposure of the lesion.

The principle of the trans-nasal canthopexy, the position and direction of the holes are of cardinal importance because they will determine the precise alignment of the canthopexy (Robert, 1984; Charles, 2002; Gruss, 1982; Joseph et al., 1990; Glen and Byron, 1990; Williamson et al., 1981). The level of perforation of septum determines the direction of traction. On the opposite lateral nasal wall the holes is made at the level of the anterior lacrimal crest and in front of tendon insertion, as is comparable to what is preferred by many previous authors (Brett, 2003; Gullane and Gilbert, 1985; Dagum et al., 1995).

It is not easy to perform such precise and delicate surgery as medial and lateral canthal tendon both of which attach to the bony margin of the orbit behind the plane of cornea (Cohen et al., 1995; Bron, 1997). Robert H. Mathog describes a technic in which two ends of the ligature wires are twisted together over a small toggle, small plate or cinch pin which lies across the hole in the contra lateral side (Robert, 1984). We find that there were difficulty in securing knot over the toggle which my lead to wire stripping, some advocated using a button instead of

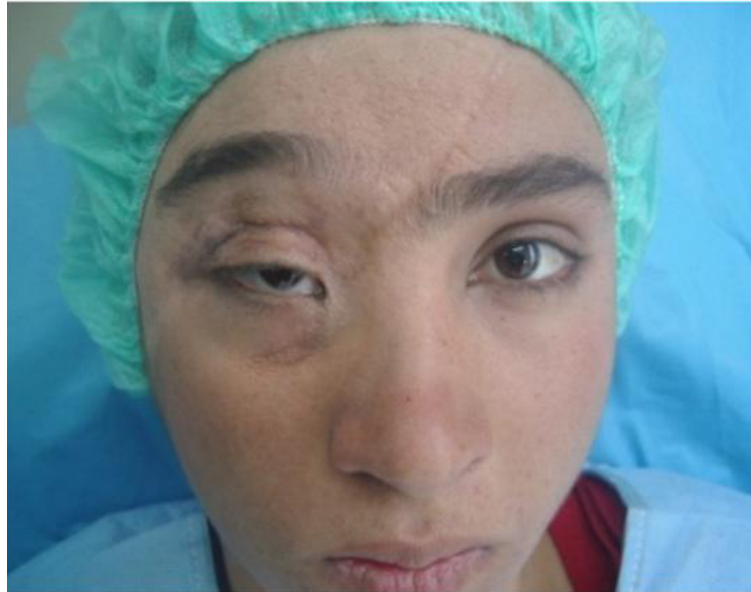

Figure 9. Pre-operative left unilateral telecanthus with downward deviation deformity

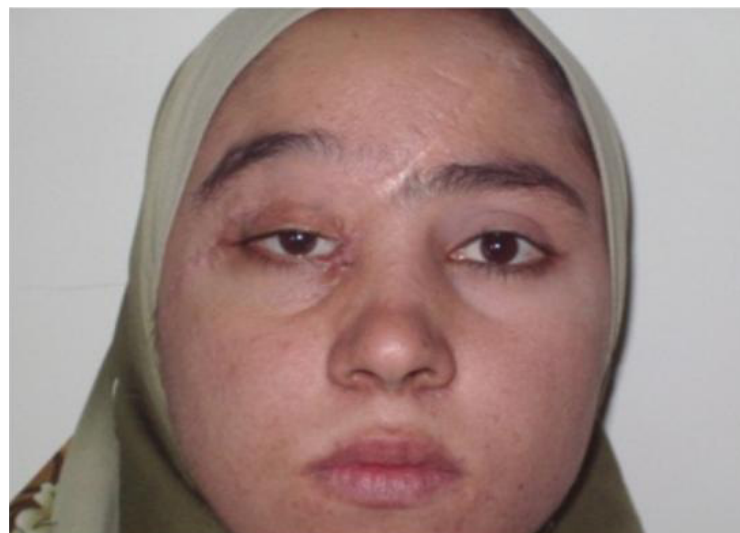

Figure 10. Post-operative View still there is rounding of the angle.

toggle. These buttons causes intense skin irritation with unrelieved pain sensation and even necrosis of the skin and such a surgical procedure need secondary surgical to remove the wire. So we suggest to use mini plate and screws to repair MCT, our technique which need wide exposure of the field obtained by Mustardea technique (jumping man approach), figure 8, or by the original scar.

Using miniplate and screws we can provide precise alignment of the canthal tendon. We can adjust the level of medial canthal ligament attachment precisely, can provide the proper length of tendon, provide better

symmetrical appearance, it can be used to reposition the MCT even in case of severe trauma with destruction of most of the tendon as we can use the fibrous tissue in continuity with the tendon to be inserted beneath the plate figure as advocated in previous authors (Joseph et al., 1990). The access to the area was through Mustardea in 70% of the cases to overcome tension on the site of the medial canthal tendon repair and to override scar contracture and to correct medial epicanthal fold, it is a single stage surgery.

The average times of surgery were 45 minutes. In

group one post-operative asymmetry noticed in three patients, deviated angle in two patients and rounded angle in other two. Functionally there were persistence epiphora in two patients and the mean post-operative CI was 33.72 with mean advancement of MCT. While ingroup two asymmetry was noticed in one patient, rounded angle in one patient and the mean post-operative CI was 31.05 and persistence epiphora only in one patient. The above result shows that better esthetic and functional result gain with mini plate and screws medial canthopexy.

In all group one patients we faced a problem of awling through the nasal bones where there were 2-3 times failed trail, and the other problem was profuse bleeding during surgery in both group in the first four cases and it is treated by cauterization of angular vessels and then elective cauterization of angular vessels was a role to avoid such a problem, that was against Andrei M. Varviniski who stated that the angular vessels are avoidable. Complications: in addition to those mentioned above, wire stripping were recorded in two cases in group one that might be either due to inadequate stabilization over the toggle that used or to the type of stainless steel wire used, where there was difficulty in securing knot over the toggle. Secondary operation was done for those two patients using a button instead of toggle.

CONCLUSION AND RECOMMENDATION

Elective cauterization of the angular vessels facilitates the surgery. Mini plate and screws canthopexy is a short surgical procedure provides precise alignment of the MCT and provide better post-operative symmetrical appearance, and better aesthetic and functional result can be gained figure (10). Other studies are needed to confirm or dispute this hypothesis. Age and sex

distribution confirm the fact that during the war conflict all the people will be a victim to the violence. (Figure 9 and 10)

REFERENCES

- Anthony JM (1983). The Otolaryngologic clinic of North America Aug. page 590.
- Brett O. Donnell (2003). Repair of lax MCT, British Journal of Ophthalmology, :-80-87:- 220-224.
- Bron AG (1997). Wolff's Anatomy of the Eye and Orbit 8th page 1-3.
- Charles NS (2002). Seminars in plastic surgery august. p. 332.
- Cohen MM, Rechieri-Costa A, Guion Almeida, Saverdra (1995). Hypertelorism, interorbital growth, measurement, and pathogenic consideration, int. journal oral maxillofacial. Surgery; 24-387.
- Dagum AB, Antonyshyn O. Hearn T (1995). Annular plastic surgery sept. 35 p. 262.
- Evans AT (1994). Row and William's maxillofacial injury 2nd edition chapter 22 page 933.
- Frodel JL (1995). Management of nasal dorsum in central facial injury, Otolaryngology Head Neck Surgery:-121-307.
- Glen W. Jalk and Byron C (1990). Smith plastic surgery vol. 2 part 1 chapter. 34 page 1777.
- Gruss JS (1982). fronto-naso-orbital trauma, clinic in plastic surgery;-9 577 24.
- Gullane PJ, Gilbert RW (1985). Approach to naso-frontal-ethmoidal complex fracture. J. Otolaryngology, 14:132
- Joseph G. McCarthy, Glenn W. Jelks, August and NSJ. Valauri Donald Wood, Smith. B (1990). Smith plastic surgery. Vol. 2 part 1 q chapter 33 1611.
- Kala ND, Vrezos KW, Greatz GK, Eyrich and HF, Sailer JR (2000). Coll Surgery. Edinburgh 45, December page 359.
- Michael Bryan MD (1996). under supervision Francis B. Quinn, Jr. M.D. Midface fracture A thesis submitted to department of Otolaryngology, Head and Neck Surgery.
- Robert H. Mathog (1984). Maxillofacial trauma, second edition, chapter 24 p.303
- Williamson LK, Miller RH, Session R.B (1981). Treatment of naso fronto ethmoidal fractures, Otolaryngology head and neck surgery; 89 ;587.