

Case Report

Gigantic Medullary Breast Cancer

Ibrahim Albalawi

Associate Professor, Department of
Surgery, Faculty of Medicine,
University of Tabuk, P.O.Box:4333-
Tabuk 71491 Kingdom of Saudi
Arabia.

Email: drbalawi@yahoo.com
Tel.: 00966555668449

Medullary breast cancer is a rare type of breast cancer in Saudi Arabia and all over the world. It can be difficult to diagnose and may sometimes overlap with benign lesion such as fibroadenoma on conventional imaging. It has high grade cytology and a syncytial growth pattern and very good prognosis. We report a 32-year-old, single female patient with a huge 20 x 10cm painless firm to hard mass with variable consistency involving almost whole of the right breast

Keywords: Breast, Carcinoma, Mastectomy Medullary, Prognosis

INTRODUCTION

Breast cancer is common worldwide, in the United States of America, 240000 new cases are diagnosed every year. Medullary breast cancer is a rare type of invasive ductal breast cancer. It accounts 1-7% of all breast cancers (Li, 2010). Medullary breast cancer is less common among carriers of the BRCA-1 genetic mutation.

Moore and Foote (1947) described the unique histological features of medullary breast cancer as high-grade structure, with sharp circumscription, dense infiltration with lymphocytes, hemorrhagic necrosis, and favorable prognosis (Moore OS, 1949; Cotran, 1999).

Strict histopathological features should be fulfilled before the firm diagnosis of medullary carcinoma of the breast is made. Due to the subjectivity of histopathological grouping of the breast cancer and interobserver variability. Ridolfi and his colleagues in the year 1977 set up criteria for the diagnosis of medullary carcinoma that included the presence of the following: microscopic circumscription, high nuclear grade, infiltration by lymphoplasmacytic cells, syncytial growth pattern in at least 75% of the areas examined, the absence of tubular differentiation and an intraductal component (Kempson, 2006).

Previous literature has indicated that despite the presence of aggressive features like large size of the tumor, high nuclear grade, and negative hormone receptors, the tumor behave less aggressively and have a favorable prognosis (Li, 2005; Vu-Nishino, 2005).

There is dispute about medullary carcinoma of the breast among scientists; some regard it as a mark of invasive ductal carcinoma while other distinguish the tumor as different nosological unit (Romaniuk, 2015)

CASE REPORT

A 32-year-old, single, nulliparous, premenopausal Saudi lady presented to us with a huge lump in her right breast, noticed about nine months ago. It was small in size at the time of presentation to her primary physician. She consulted a surgeon at another hospital and the lump was excised. Histopathology report came as benign mass. But the mass recurred after two months and attained massive proportions. She had no family history of the breast or ovarian cancer.

When we first see her, she was very pale and febrile with a temperature of 40⁰ C due to local infection. Her right breast was huge in size when compared to the opposite side. Her right breast contained 20x10cm painless firm to hard mass with variable consistency (Figure 1A). The overlying skin is stretched out, thin, shiny and fixed to the mass, with areas of pressure necrosis and ulceration. The mass had only limited mobility over the underlying structures. Nipple and areola appeared to be normal. There were two palpable, mobile lymph nodes in the right axilla.

No hepatomegaly or ascites were detected, either clinically or radiologically. Her hemoglobin was 4.5g/dl, and total leucocyte count 24000. Ultrasonogram and mammograms of right breast revealed a heterogeneous mass with solid and cystic components, and enlarge axillary lymph nodes. Computed tomography was suggestive of underlying muscle invasion. Cytologic study of the FNA was reported as adenocarcinoma. The diagnosed was Carcinoma Rt breast T4 N1 M0.

Modified Radical mastectomy was done after transf-

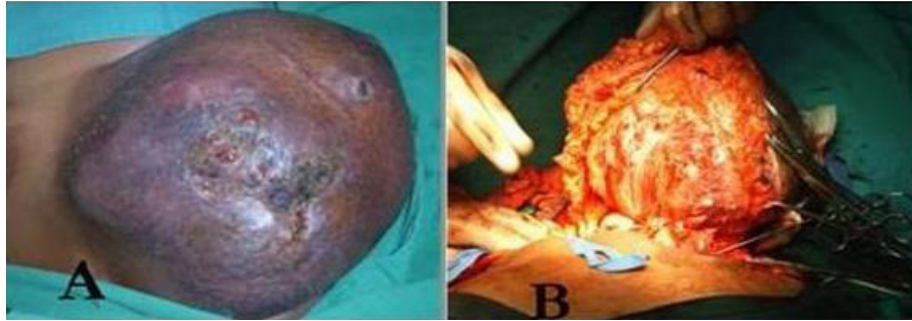

Figure 1A. Rt breast pre-operative

B. Rt breast intra-operative

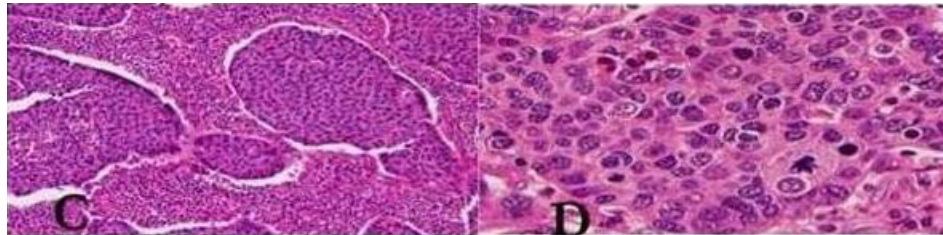


Figure 2. C. High nuclear grade

D. Infiltration by lymphoplasmacytic cells

using three units of blood pre-operatively. Level II axillary dissection was done (Figure 1B). Histopathologic examination revealed medullary carcinoma, with a tumor size of 18 cm at maximum dimensions, with skin infiltration. All surgical margins were free, closest being the deep margin, about 0.1 cm from the tumor. There was high nuclear grade and infiltration by lymphoplasmacytic cells (Figure 2C and D). The rest of the breast was unremarkable. 3 out of 17 axillary nodes showed metastasis, largest being 0.1cm

The patient had uneventful recovery post-operatively and was sent for further adjuvant therapy.

DISCUSSION

Worldwide 1.2 million women diagnosed with breast cancer annually, one broad entity is the infiltrative ductal carcinoma which comprises tumors that contain one or more of the specific features of breast cancer. Microscopically medullary, papillary, mucinous, and tubular differentiation may be evident. Although the etiology is still unknown, the association of medullary breast cancer with BRCA1 is suggested (WHO –EMRO, Ridolfi, 1977; Marcus, 1996).

Strict histopathological features should be fulfilled before the firm diagnosis of medullary carcinoma of the breast is made. Due to the subjectivity of histopathological grouping of the breast cancer, and interobserver variability (Sloane, 1994). Ridolfi and his colleagues in the year 1977 set up criteria for the

diagnosis of medullary carcinoma that included the presence of the following:

- a. Microscopic circumscription.
- b. High nuclear grade.
- c. Infiltration by lymphoplasmacytic cells.
- d. Syncytial growth pattern in at least 75% of the areas examined.
- e. The absence of tubular differentiation and an intraductal component (Moore, 1949).

If all the above-mentioned criteria are present a diagnosis of classic medullary is made, if one or two of the above features are absent Atypical medullary carcinoma is used, ductal carcinoma' not otherwise specified (NOS) is applied when there is poor correspondence within the five categories.

The diagnosis of medullary breast carcinoma is essentially histopathological, but certain features on mammography may point towards malignant potential, speculated or irregular shape, irregular margin, and high density of the lesion. In comparison to healthy breast tissue, the density can be described as high, intermediate, and low density with the latter suggesting a benign course. The mammographic features cannot rely on differentiating between benign and malignant lesion, the following point to malignant potential: thick echogenic or speculation halo, micro lobulations, hypoechogenicity, calcification, acoustic shadowing, duct extension and branch pattern (Rumack, 1991).

Medullary carcinoma of the breast cannot be differentiated from other types of breast cancer based on ultrasonographic features of the lymph nodes, but malignancy is suggested by the presence of

an abnormal outward contour and round shape of the lymph node. The appearance of the lymph node cortex and a thickness greater than 2.3mm suggest lymph nodes metastasis (Deurloo, 2003).

Recent literature provides a classification based on gene expression with extensive heterogeneity (ER, PR, and HER negative, with some ER, PR, and HER positive reports) (Jacquemier, 2005). In the present report the tumor was ER, PR, and HER negative.

Some reports suggested that well-circumscribed masses and the absence of posterior acoustic shadow on imaging typical favor carcinoma, although histopathology is always needed (Yilmaz, 2002).

The presence of lymphocytes and plasma cells in the medullary carcinoma is suggested for the slow growth and favorable prognosis than invasive ductal carcinoma (90% 10 years survival rate in those without lymph nodes involvement) furthermore pure medullary cancer has a better prognosis than ones with atypical features making strict adherence to diagnostic criteria more necessary (Jensen, 1997; Kuroda, 2005; Reinfuss, 1995).

The Classification of typical and atypical subtypes has prognostic significance and does not modify treatment options. The treatment for all typical, a typical or invasive ductal carcinoma is similar: depending on the stage or histologic grade modified or radical mastectomy along with radiation or chemotherapy grade (Rosen, 2001).

CONCLUSION

Medullary breast carcinomas are rare type of breast cancer consisting of high grade cytology and a syncitial growth pattern. The prognosis of medullary carcinoma is very good. Strict histopathological features should be fulfilled before the diagnosis of medullary carcinoma.

REFERENCES

Cotran RS, Kumar V, Collins T, Robbins SL (1999). Robbins Pathologic Basis of Disease. 6th ed. Philadelphia: Saunders; p. 1111
Deurloo EE1, Tanis PJ, Gilhuijs KG, Muller SH, Kröger R, Peterse JL, Rutgers EJ, Valdés Olmos R, SchultzeKool LJ (2003). Reduction in the number of sentinel lymph node procedures by preoperative ultrasonography of the axilla in breast cancer. *Eur J Cancer*;39:1068–1073.

Jacquemier J1, Padovani L, Rabayrol L, Lakhani SR, Penault-Llorca F, Denoux Y, Fiche M, Figueiro P, Maisongrosse V, Ledoussal V, Martinez Penuela J, Udvarhelyi N, El Makdissi G, Ginestier C, Geneix J, Charafe-Jauffret E, Xerri L, Eisinger F, Birnbaum D, Sobol H (2005). Typical medullary breast carcinomas have a basal/myoepithelial phenotype. *J Pathol*;207:260-268.
Jensen ML, Kiaer H, Andersen J, Jensen V, Melsen F (1997). Prognostic comparison of three classifications for medullary carcinomas of the breast. *Histopathology*; 30:523–532.
Kempson RL, Rouse RV (2006). *Surgical Pathology Criteria*. Stanford School of Medicine; Available at: <http://www.surgpathcriteria.stanford.edu>
Kuroda H, Tamaru J, Sakamoto G, Ohnisi K, Itoyama S (2005). Immunophenotype of lymphocytic infiltration in medullary carcinoma of the breast. *Virchows Arch*;446:10–4.
Li CI (2010). The risk of mortality by histologic type of breast cancer in the United States. *Horm Cancer*;1:156–165. (a).
Li CI, Uribe DJ, Daling JR (2005). Clinical characteristics of different histologic types of breast cancer. *Br J Cancer*;93:1046–1052. [PMC free article] [PubMed].(b)
Marcus JN1, Watson P, Page DL, Narod SA, Lenoir GM, Tonin P, Linder-Stephenson L, Salerno G, Conway TA, Lynch HT (1996). Hereditary breast cancer: pathobiology, prognosis, and BRCA1 and BRCA2 gene linkage. *Cancer*. 77:697–709.
Moore OS, Jr, Foote FW., Jr (1949). The relatively favorable prognosis of medullary carcinoma of the breast. *Cancer*. 2:635–642. [PubMed]
Reinfuss M, Stelmach A, Mitus J, Rys J, Duda K (1995). Typical medullary carcinoma of the breast: a clinical and pathological analysis of 52 cases. *J SurgOncol*;60:89–94.
Ridolfi RL, Rosen PP, Port A, Kinne D, Mike V (1977). Medullary carcinoma of the breast: a clinicopathologic study with 10 year follow-up. *Cancer*. 40:1365–1385.
Romaniuk A1, Lyndin M, Sikora V2, Lyndina Y, Panasovska K (2015). Histological and immunohistochemical features of medullary breast cancer. *Folia Med Cracov*;55(2):41-8.
Rosen PP (2001). Medullary Carcinoma. In: *Rosen's Breast Pathology*. 2nd Edition Lippincott Williams & Wilkins, Philadelphia, pp. 405-422
Rumack CM, Wilson SR, Charboneau JW (1991). *Diagnostic Ultrasound*, Volume 1. St. Louis, pp. 812-821.
Sloane JP, Ellman R, Anderson TJ, Brown CL, Coyne J, Dallimore NS, et al. Consistency of histopathological reporting of breast lesions detected by screening: findings of the UK National External Quality Assessment (EQA) Scheme. *Eur J Cancer*. 1994; 30A:1414–1419.
Vu-Nishino H, Tavassoli FA, Ahrens WA, Haffty BG (2005). Clinicopathologic features and long-term outcome of patients with medullary breast carcinoma managed with breast-conserving therapy (BCT) *Int J RadiatOncolBiol Phys*. 62:1040–1047.
World Health Organization (WHO). Eastern Mediterranean Regional Office (EMRO). Non communicable diseases. Available at: http://www.emro.who.int/ncd/cancer_breast.htm
Yilmaz E, Lebe B, Balci P, Sal S, Canda T (2002). Comparison of mammographic and sonographic findings in typical and atypical medullary carcinomas of the breast. *ClinRadiol*; 57:640–5